

FOV 240/1.1
Slice 9/25 TR 7000
eFLAIR TRA TE 90

11-06-1984
18-09-2017
97
M



CORTECHS Labs

LesionQuant

Lesions, Quantified.

**FAST,
ACCURATE, &
PROVEN**



CORTECHS Labs

www.cortechslabs.com

info@cortechslabs.com • +1 858.459.9700

Fast and Accurate FLAIR Lesion Quantification and Visualization with LesionQuant

- ✓ Comprehensive FLAIR lesion segmentation and identification within minutes
- ✓ Color-coded slice-by-slice review of resolving, stable, or active lesions via FLAIR overlay available directly on your PACS or DICOM viewer
- ✓ Precise quantitative measurements aid in clinical assessment, treatment planning, and disease progression monitoring
- ✓ Verified, optimized, and trusted automated image analysis

The LesionQuant Difference

- ✓ Powered by NeuroQuant and Dynamic Atlas
- ✓ The LesionQuant module of NeuroQuant is FDA cleared, CE marked, and Health Canada, Australia, and Korea licensed
- ✓ Fully automated, consistent, and reproducible results
- ✓ Lesion change overlays to identify volume change and detect new, active, and resolving lesions
- ✓ Anatomical segmentation overlay and brain volumes of 8 important regions compared to healthy normative values for ages 3 to 100
- ✓ Easy-to-read reports for single time point analysis and change analysis for lesion counts and lesion volumes
- ✓ Summary of lesion results ready to be included in a physician's report
- ✓ Combines information from 3D T1 and 2D or 3D FLAIR MR imaging
- ✓ Compatible with 1.5 T and 3.0 T GE, Philips, Siemens and Toshiba, and 1.2 T, 1.5T and 3.0T Hitachi scanners

LesionQuant™ FLAIR Lesion Report PLUS

CorTechs Labs, Inc
Address line 1
Address line 2
Preferred contact info

PATIENT INFORMATION

Version 3.0.0

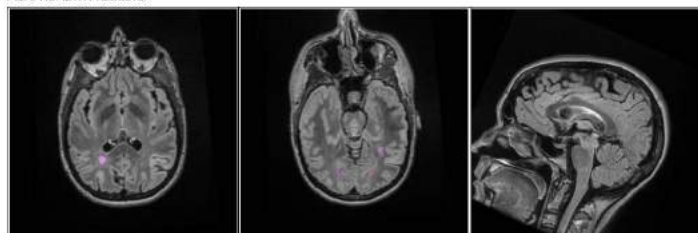
Patient ID:	Patient Name:	Sex: F	Age: 33	Referring Physician:
-------------	---------------	-----------	------------	----------------------

SCAN INFORMATION

LESION SETTINGS

Scan Date	Accession Number	Lesion Size	Lesion Separation	Infratentorial	Leukocortical	Periventricular	White Matter
2017-06-12		1 mm ³	2 mm	1.0	1.0	1.0	1.0
2017-01-30		1 mm ³	2 mm	1.0	1.0	1.0	1.0

MORPHOMETRY RESULTS



Brain Structure	Current Scan			Prior Scan			Change		
	Volume (cm ³)	% ICV	Norm ative Percentile	Volume (cm ³)	% ICV	Norm ative Percentile	Volume Change (cm ³)	Volume Change (%)	Norm Percentile Change
Whole Brain	1151.52	79.97	62	1160.25	79.43	70	-8.74	-0.8	-8
Superior Lateral Ventricles	29.65	2.03	96	29.12	1.99	95	0.53	1.8	1
Thalamus	14.73	1.01	95	14.98	1.03	97	-0.26	-1.7	-2
Cortical Gray Matter	526.06	36.08	63	520.59	35.64	54	5.47	1.1	9
Cerebral White Matter	414.52	28.43	33	425.05	29.10	51	-10.54	-2.5	-18
3rd Ventricle	1.24	0.09	89	1.23	0.08	89	0.01	0.6	0
Hippocampi	7.12	0.49	23	6.98	0.48	16	0.14	2.0	7
Inferior Lateral Ventricles	1.00	0.07	61	1.06	0.07	67	-0.06	-5.4	-6

LESION RESULTS

	Total Lesions	Leukocortical	Periventricular	Infratentorial	Deep White
Count	66	23	17	1	25
Volume (cm ³)	3.61	0.99	1.66	0.02	0.94
Lesion Burden	0.87				

LESION CHANGE

Counts	Total Lesions	Leukocortical	Periventricular	Infratentorial	Deep White
New	1	0	0	0	1
Enlarging	0	0	0	0	0
Shrinking	2	0	1	0	1
Total Change	2	11	-4	-4	-1
Volumes (cm ³)	Total Lesions	Leukocortical	Periventricular	Infratentorial	Deep White
New	0.24	0.00	0.00	0.00	0.24
Enlarging	0.00	0.00	0.00	0.00	0.00
Shrinking	0.13	0.00	0.09	0.00	0.04
Total Change	-2.23	0.39	-1.22	-0.04	-1.36

A NeuroQuant® Product

 CorTechs Labs | cortechslabs.com

- ✓ Count, volume, and percent of intracranial volume of all new, enlarging, and shrinking lesions
- ✓ White matter lesion burden calculation
- ✓ Anatomical distribution of lesions by volume and count

LesionQuant™ FLAIR Lesion Report PLUS

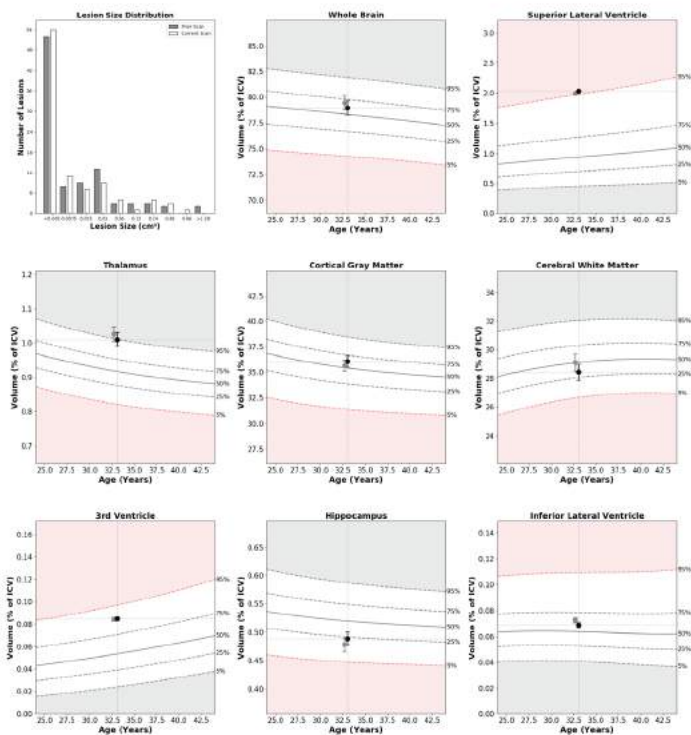
CorTechs Labs, Inc
Address line 1
Address line 2
Preferred contact info

PATIENT INFORMATION

Version 3.0.0

Patient ID:	Patient Name:	Sex:	Age:	Referring Physician:
		F	33	

AGE AND GENDER MATCHED REFERENCE CHARTS



A NeuroQuant® Product

 CorTechs Labs | cortechslabs.com

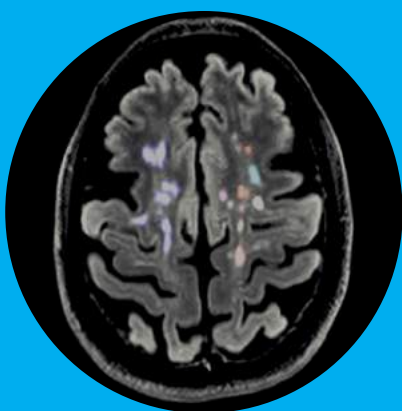
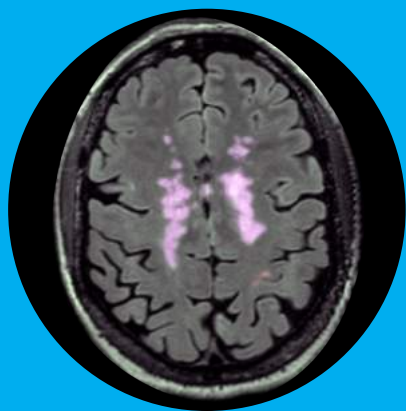
- ✓ Histogram of lesion volume distributions
- ✓ Current volume and normative percentile change of 8 brain structures with age and sex-matched reference charts

LesionQuant Color-Coded FLAIR Lesion Overlay on PACS or DICOM Viewer

Lesion Segmentation:

By Anatomical Region

By Individual Lesion



Lesion volume change from a prior scan,
colored by stable, active, and resolving lesion
status

